Tissue of Human Body

- A group of cells similar in structure (due to common embryonic origin) and function is known as tissue.
- *The four basic types of tissues in the human body contribute to homeostasis by providing diverse functions including protection, support, communication among cells, and resistance to disease, to name just a few.*

Classification of Tissue

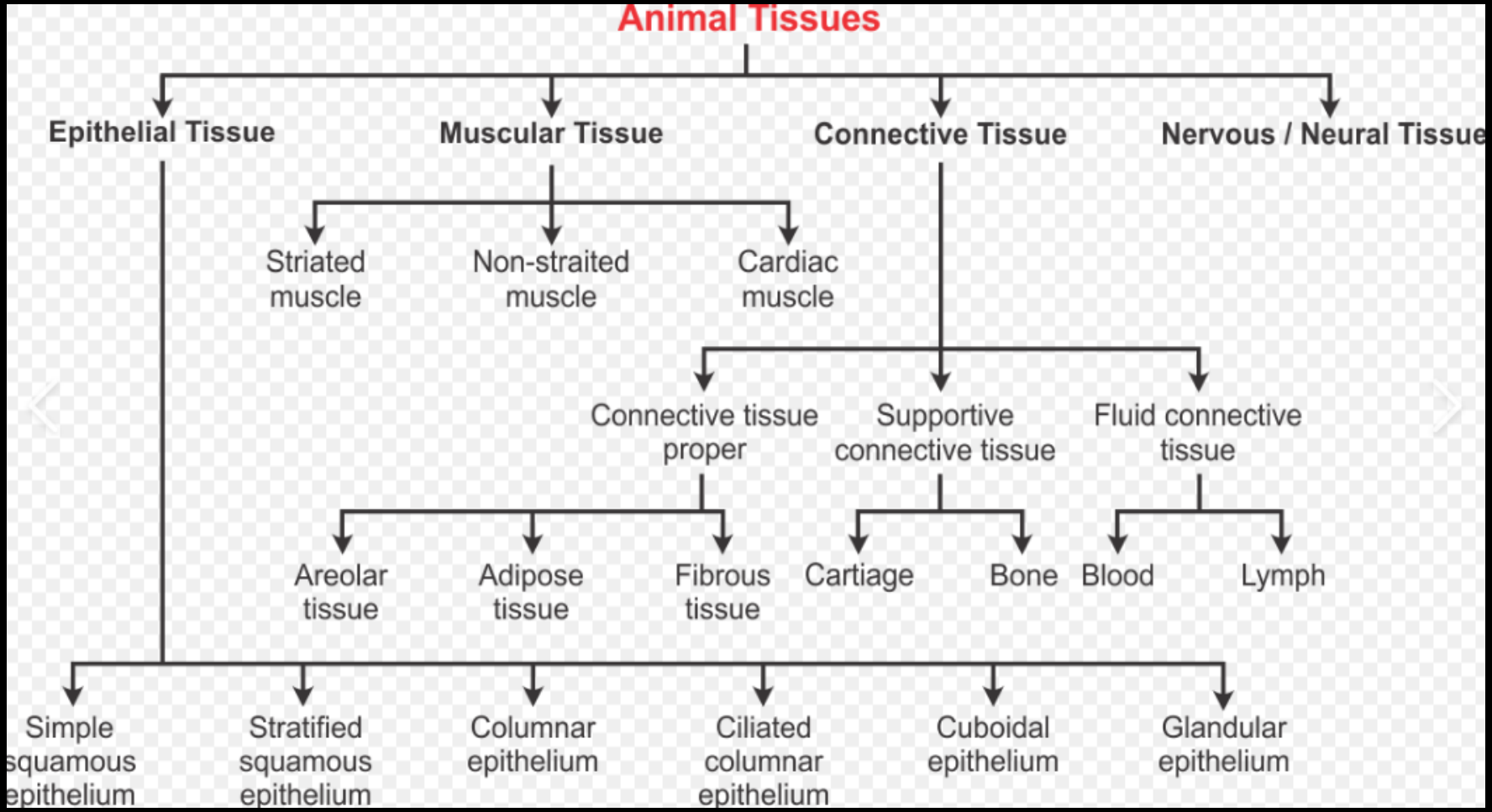

- **Histology** is the science that deals with the Microscopic study of tissues.
- Pathophysiology: The study of abnormal changes in body functions that are the causes, consequences, or concomitants of disease processes.

1. Epithelial tissues cover body surfaces and line hollow organs, body cavities, and ducts; they also forms glands. This tissue allows the body to interact with both its internal and external environments.

2. Connective tissues protect and support the body and its organs. Various types of connective tissues bind organs together, store energy reserves as fat, and help provide the body with immunity to disease-causing organisms.

3. Muscular tissues are composed of cells specialized for contraction and generation of force. In the process, muscular tissues generate heat that warms the body.

4. Nervous tissue detects changes in a variety of conditions inside and outside the body and responds by generating electrical signals called nerve action potentials (nerve impulses) that activate muscular contractions and glandular secretions.

Structure of Tissue

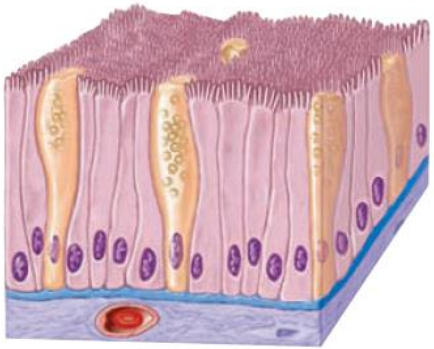

(a) Epithelial tissue

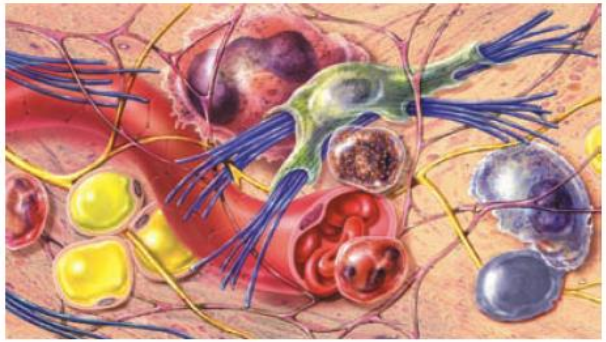

(b) Connective tissue

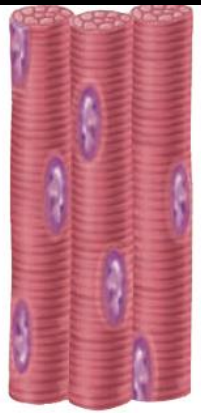

(c) Muscular tissue

(d) Nervous tissue

? What are some key differences in function among the four tissue types?

EPITHELIAL TISSUES

Most important feature of epithelial tissue is that cells are closely packed together with very little intercellular substance.

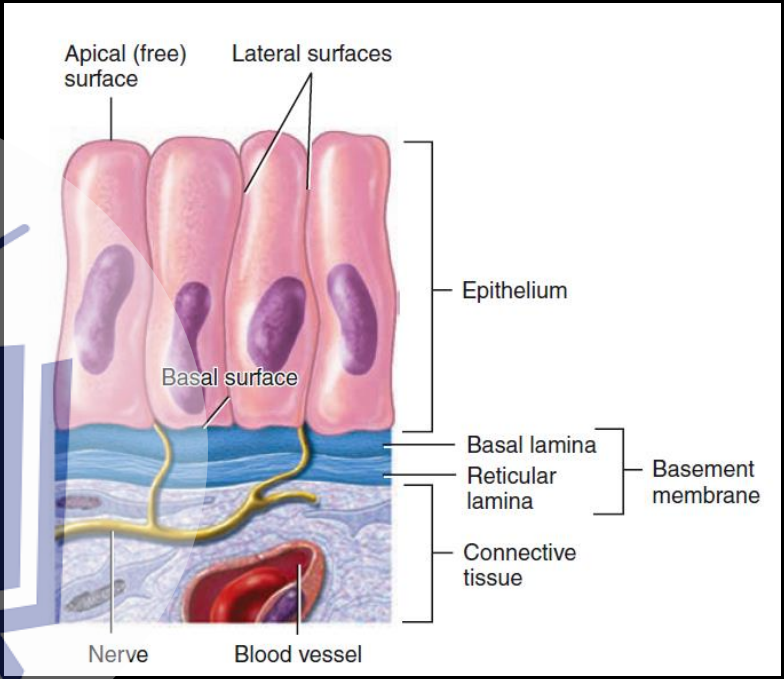

Apicial (Free) Surface: It faces the body surface. It may contain body cavity, the lumen of internal organ that receives secretions. It may contain cillia , microvilli

Lateral Surface: It Faces the adjacent cells on either side. It may contain tight junctions, adherens Junction, gap junction.

Basal Surface: It is present opposite to apical surface. In multiple layers of epithelial cells, It is deepest layer of cells.

Location

- Body surface
- Lines of body cavities
- Inner coat of blood vessels
- Lymphatic system
- Endocrine & Exocrine Glands

Functions

- Protection of body (From Skin Layer)
- Absorption (In body Cavities)
- Excretory (Sweat From Skin)
- Secretory (Secretion of sebum)
- In Specialized activities contribute in sensory reception

Simple Epithelium

- A) Simple squamous epithelium
- B) Simple cuboidal epithelium
- C)Simple columnar epithelium
- D) Simple ciliated epithelium

A) Simple squamous epithelium

- **Description** Single layer of flat cells that resembles a tiled floor when viewed from apical surface; centrally located nucleus that is flattened and oval or spherical in shape.

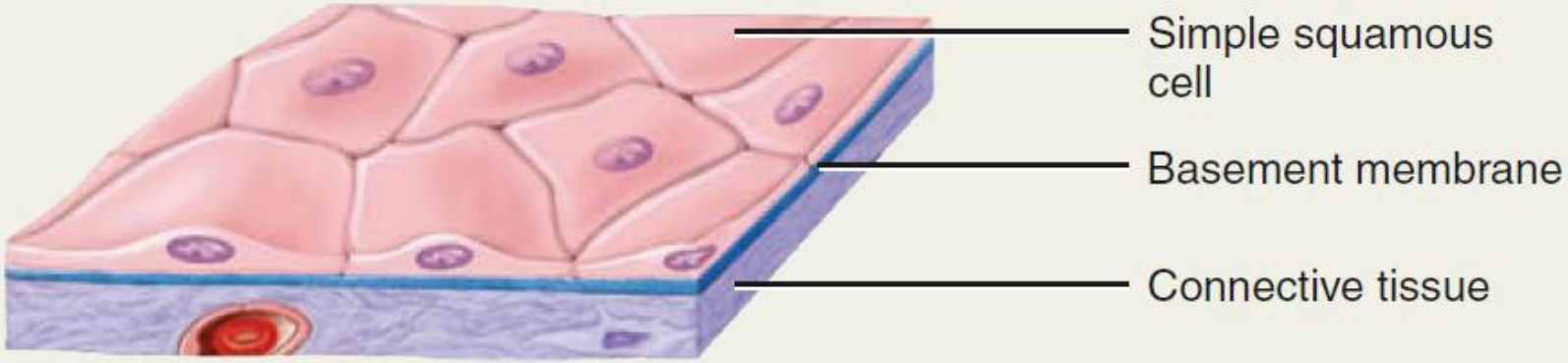

Simple squamous epithelium

Location Most commonly (1) lines the cardiovascular and lymphatic system (heart, blood vessels, lymphatic vessel linings), where it is known as **endothelium** and (2) forms the epithelial layer of serous membranes (peritoneum, pleura, pericardium), where it is called **mesothelium**. Also found in air sacs of lungs, glomerular (Bowman's) capsule of kidneys, inner surface of tympanic membrane (eardrum).

Function Present at sites of filtration (such as blood filtration in kidneys) or diffusion (such as diffusion of oxygen into blood vessels of lungs) and at site of secretion in serous membranes.

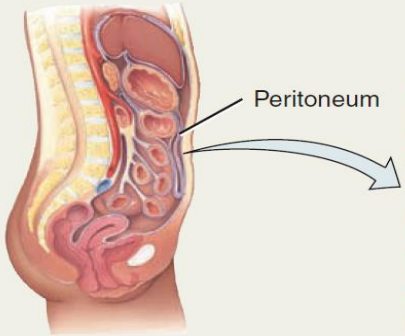

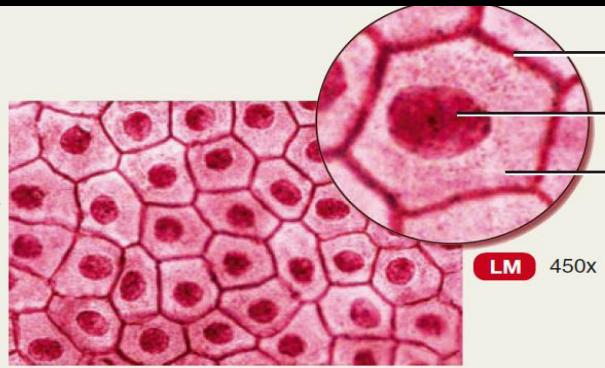

Surface view of simple squamous epithelium of mesothelial lining of peritoneum

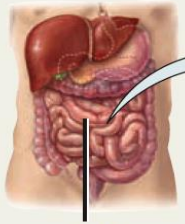

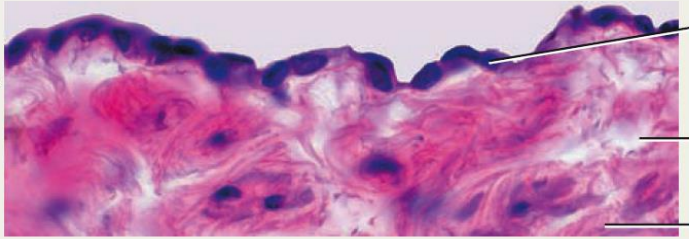

Sectional view of simple squamous epithelium (mesothelium) of peritoneum of small intestine

B) SIMPLE CUBOIDAL EPITHELIUM

Description Single layer of cube-shaped cells; round, centrally located nucleus. Cuboidal cell shape is obvious when tissue is sectioned and viewed from the side. (Note: Strictly cuboidal cells could not form small tubes; these cuboidal cells are more pie-shaped but still nearly as high as they are wide at the base.)

Location Covers surface of ovary; lines anterior surface of capsule of lens of the eye; forms pigmented epithelium at posterior surface of retina of the eye; lines kidney tubules and smaller ducts of many glands; makes up secreting portion of some glands, such as thyroid gland and ducts of some glands such as pancreas.

Function Secretion and absorption.

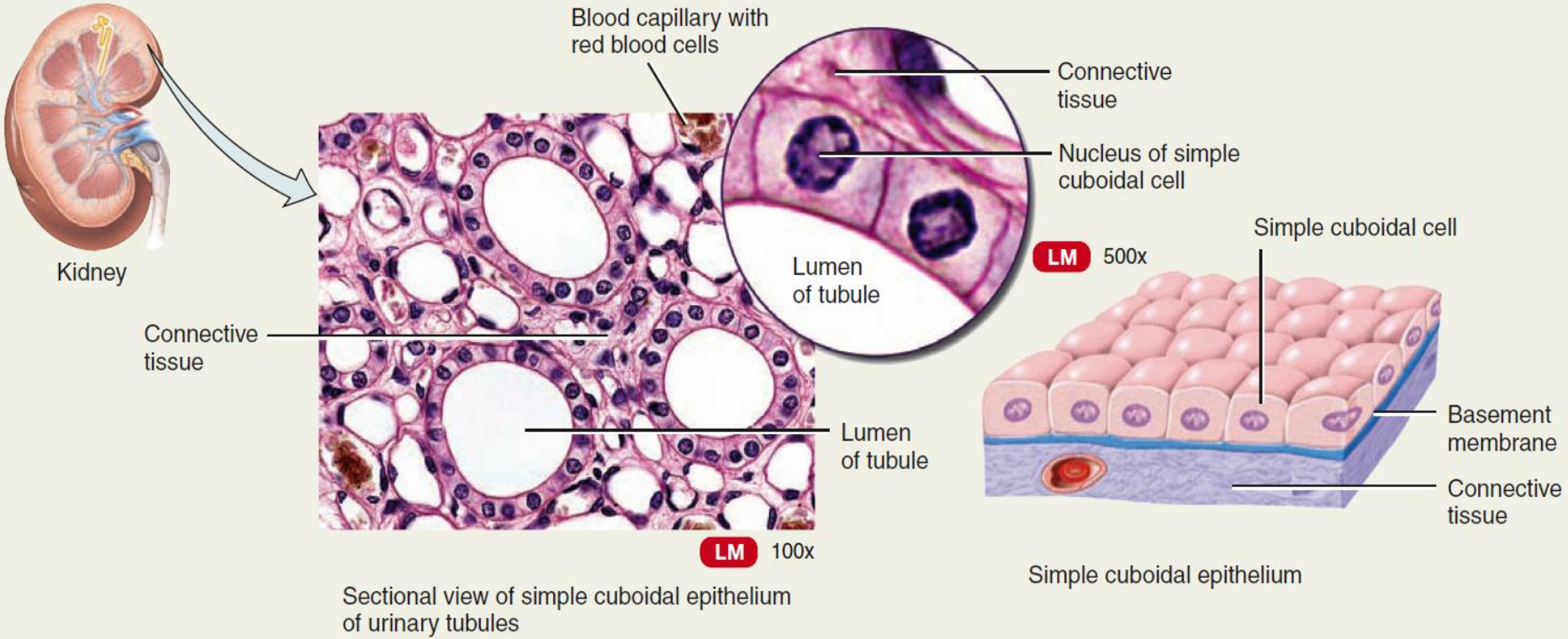

C) SIMPLE COLUMNAR EPITHELIUM

Description It is made up of single layer of rectangular cells arranged on basement membrane.
The nucleus of each cell is oval in shape and is located near the base of cell.
Mucous secreting columnar epithelium cell called as goblet cells

Location Lines gastrointestinal tract (from stomach to anus), ducts of many glands, and gallbladder.

Function Secretion and absorption; larger columnar cells contain more organelles and thus are capable of higher level of secretion and absorption than are cuboidal cells. Secreted mucus lubricates linings of digestive, respiratory, and reproductive tracts, and most of urinary tract; helps prevent destruction of stomach lining by acidic gastric juice secreted by stomach.

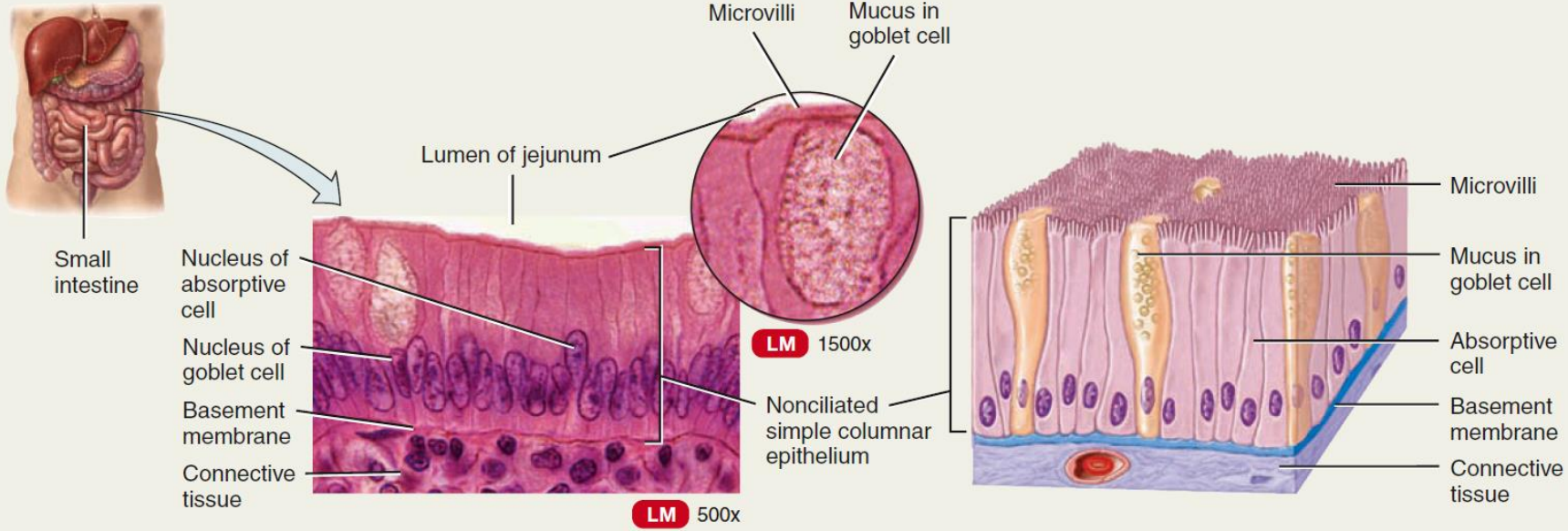

Sectional view of nonciliated simple columnar epithelium of lining of jejunum of small intestine

Nonciliated simple columnar epithelium

D) SIMPLE CILIATED EPITHELIUM

Description Single layer of ciliated columnlike cells with oval nuclei near base of cells. Goblet cells are usually interspersed among ciliated columnar epithelia.

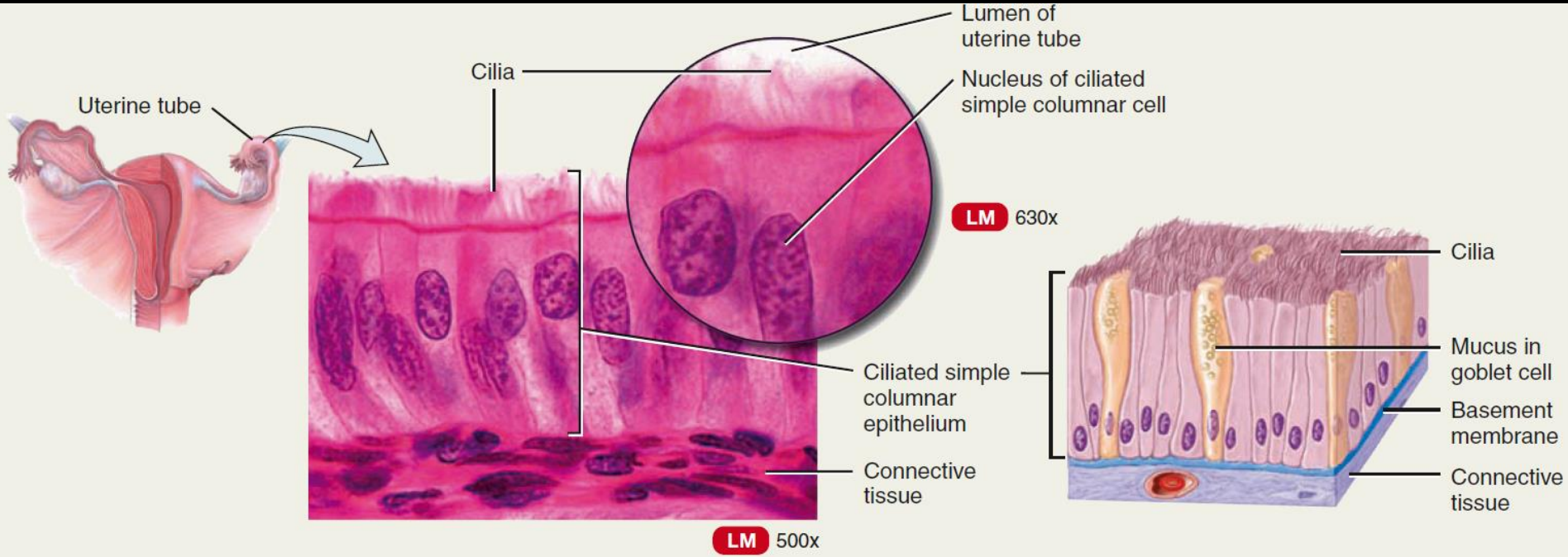

Sectional view of ciliated simple columnar epithelium of uterine tube

Ciliated simple columnar epithelium

Location Lines some bronchioles (small tubes) of respiratory tract, uterine (fallopian) tubes, uterus, some paranasal sinuses, central canal of spinal cord, and ventricles of brain.

Function Cilia beat in unison **(together, at the same time)**, moving mucus and foreign particles toward throat, where they can be coughed up and swallowed or spit out. Coughing and sneezing speed up movement of cilia and mucus. Cilia also help move oocytes expelled from ovaries through uterine (fallopian) tubes into uterus.

STRATIFIED EPITHELIUM

- STRATIFIED SQUAMOUS EPITHELIUM
- STRATIFIED CUBOIDAL EPITHELIUM
- STRATIFIED COLUMNAR EPITHELIUM
- TRANSITIONAL EPITHELIUM

STRATIFIED SQUAMOUS EPITHELIUM

Description It is composed of more than one layer of cells having different shape

- The Cells in apical layer are flat and those present in deep layers vary in shape from cuboidal to columnar
- As the cell grows their blood supply is restricted and they become dehydrated, shrunken and harder

- These tissues exist in two forms keratinised & Non-karatinised
- In keratinised stratified squamous epithelium, the apical layed and serval deep layers dehydrated and contain a layer of protein, a tough fibrous protein that helps to protect skin and underlining tissue from heat, microbes, chemicals.
- In Non-karatinised stratified squamous epithelium, keratine is absent from apicial line and they remain moist

Location Keratinized variety forms superficial layer of skin; nonkeratinized variety lines wet surfaces (lining of mouth, esophagus, part of epiglottis, part of pharynx, and vagina) and covers tongue.

Function Protection against friction, water loss, ultraviolet radiation, and foreign invasion. Both types form first line of defense against microbes

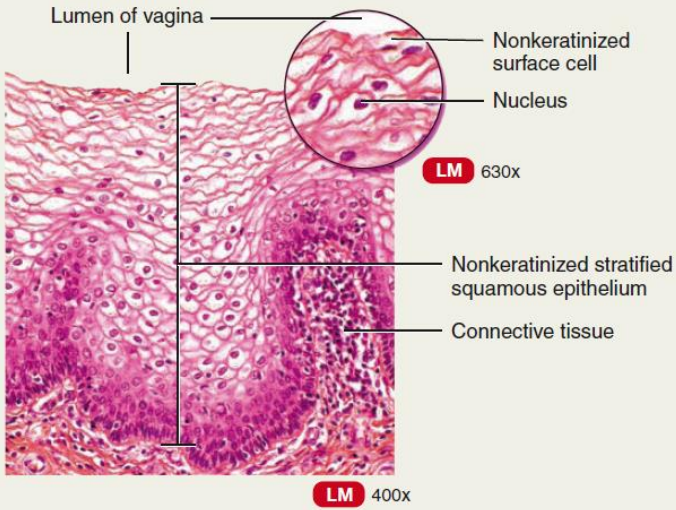

Sectional view of nonkeratinized stratified squamous epithelium of lining of vagina

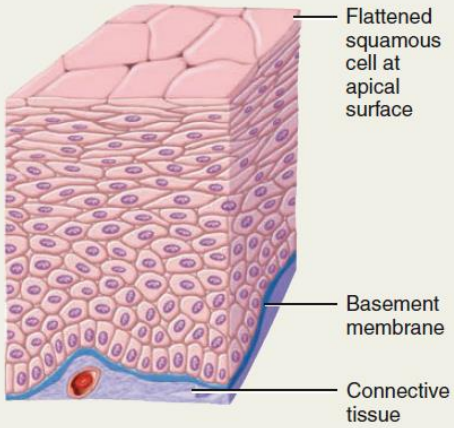

Nonkeratinized stratified squamous epithelium

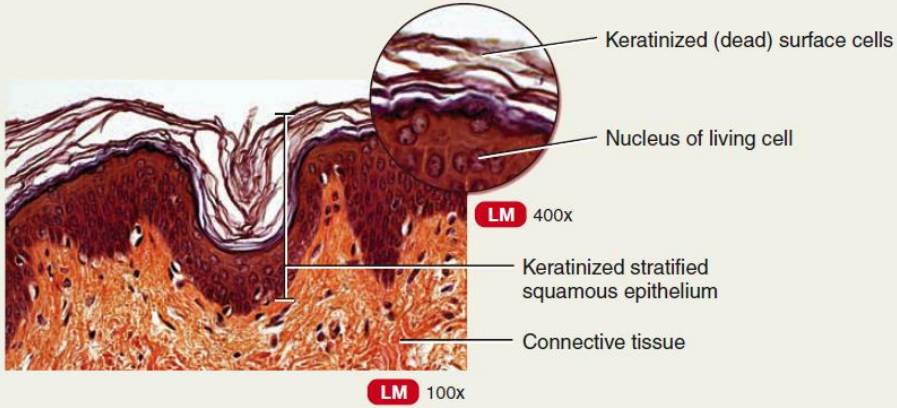

Sectional view of keratinized stratified squamous epithelium of epidermis

STRATIFIED CUBOIDAL EPITHELIUM

- **Description** Two or more layers of cells; cells in apical layer are cube-shaped; fairly rare type.
- **Location** Ducts of adult sweat glands and esophageal glands, part of male urethra.
- **Function** Protection; limited secretion and absorption.

STRATIFIED CUBOIDAL EPITHELIUM

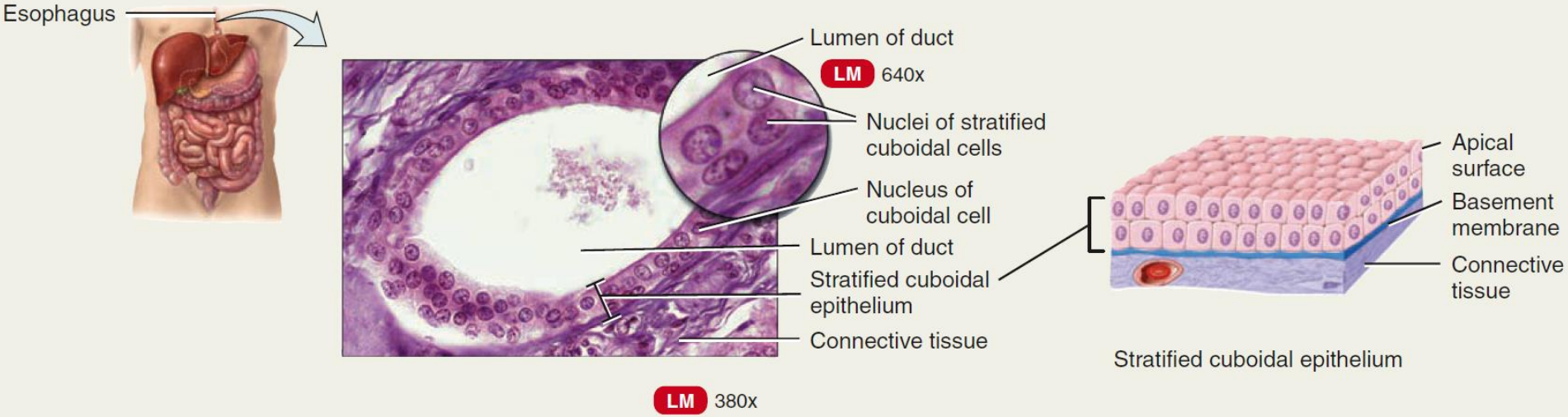

Sectional view of stratified cuboidal epithelium of the duct of an esophageal gland

STRATIFIED COLUMNAR EPITHELIUM

- **Description** Basal layers usually consist of shortened, irregularly shaped cells; only apical layer has columnar cells; uncommon.
- **Location** Lines part of urethra; large excretory ducts of some glands, such as esophageal glands; small areas in anal mucous membrane; part of conjunctiva of eye.
- **Function** Protection and secretion.

STRATIFIED COLUMNAR EPITHELIUM

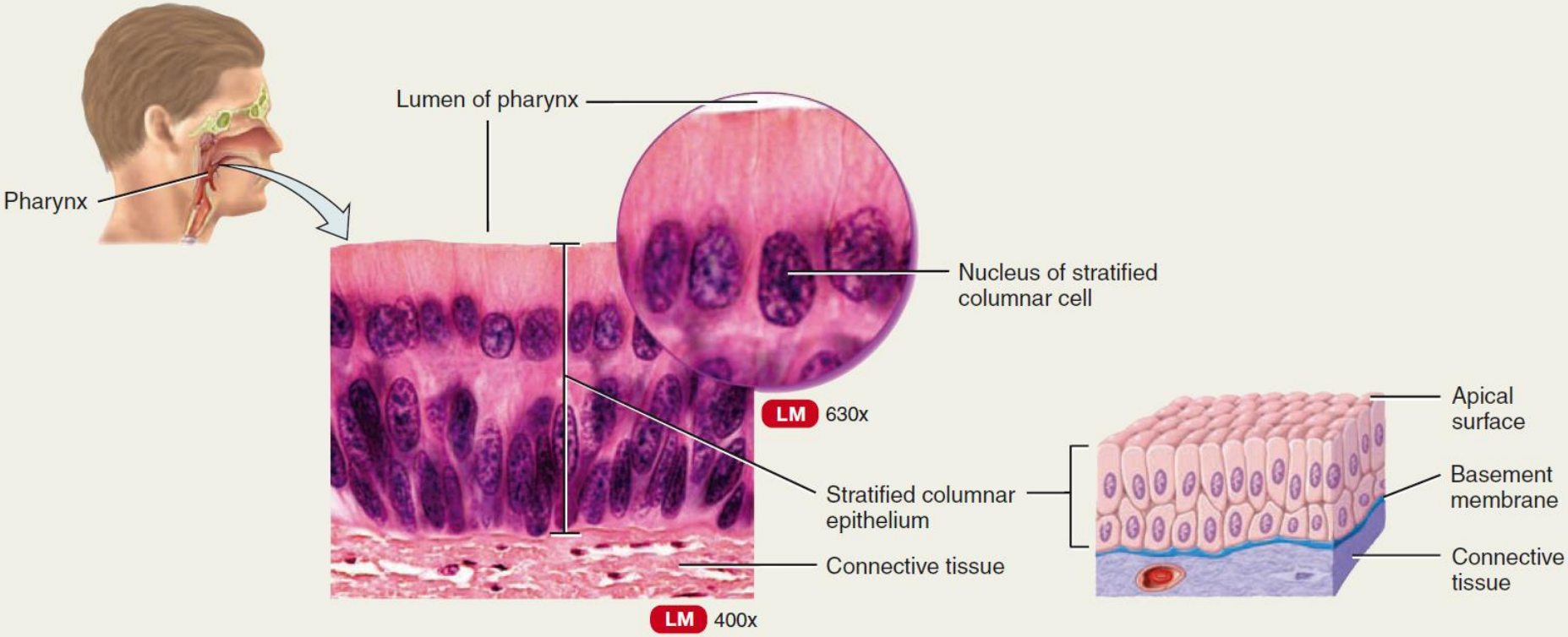

Sectional view of stratified columnar epithelium of lining of pharynx

Stratified columnar epithelium

D) TRANSITIONAL EPITHELIUM

- **Description** It consist of so many layers of pear shaped cells. The Cells are variable in appetence
- In relaxed state it looks like stratified cuboidal epithelium and when stretched then cells become squamous Shaped
- **Location** Lines urinary bladder and portions of ureters and urethra.
- **Function** Allows urinary organs to stretch and maintain protective lining while holding variable amounts of fluid without rupturing.

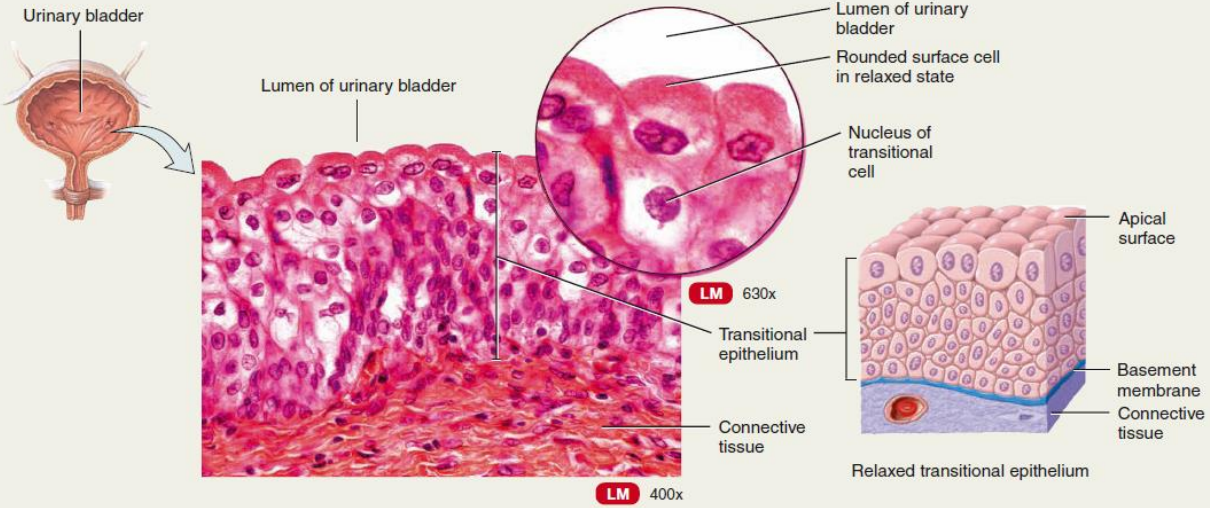

Sectional view of transitional epithelium of urinary bladder in relaxed (empty) state

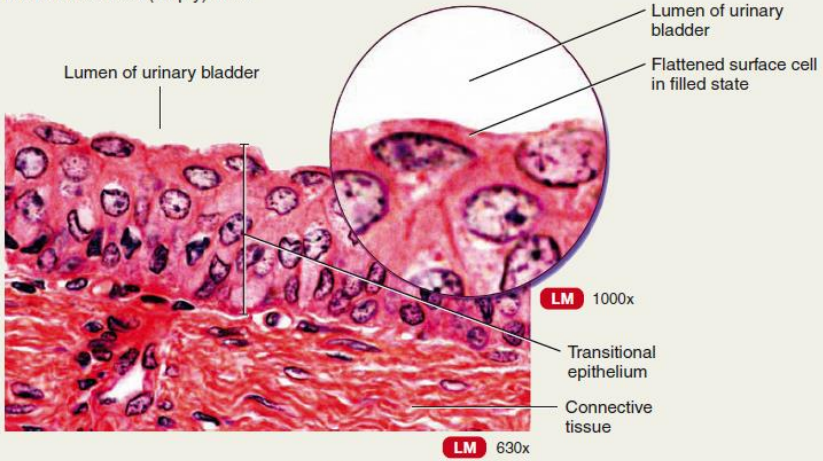

Sectional view of transitional epithelium of urinary bladder in filled state

3 PSEUDOSTRATIFIED COLUMNAR EPITHELIUM

Description The cells are columnar in shape having hair like structure at the top called cillia.

* The nucleus is oval in shaped and present at different position

* All cells are attached to the basement membrane, but not all reaches the apical surface

- **Location** Ciliated variety lines airways of most of upper respiratory tract; nonciliated variety lines larger ducts of many glands, epididymis, and part of male urethra.
- **Function** Ciliated variety secretes mucus that traps foreign particles, and cilia sweep away mucus for elimination from body; nonciliated variety functions in absorption and protection.

Glandular Epithelium

- A gland my consist of a single cell or group of cell
- They are specialised cells that secrete substance into ducts
- The glands are classified into endocrine or exocrine glands on the basis of their secretion

Endocrine Gland

- **Description** Secretions (*hormones*) enter interstitial fluid and diffuse directly into bloodstream without flowing through a duct.
- **Location** Examples include pituitary gland at base of brain, pineal gland in brain, thyroid and parathyroid glands near larynx (voice box), adrenal glands superior to kidneys, pancreas near stomach, ovaries in pelvic cavity, testes in scrotum, thymus in thoracic cavity.
- **Function** Hormones regulate many metabolic and physiological activities to maintain homeostasis.

Thyroid gland

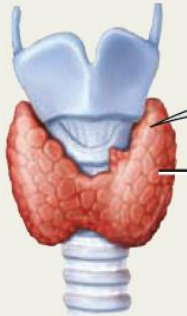

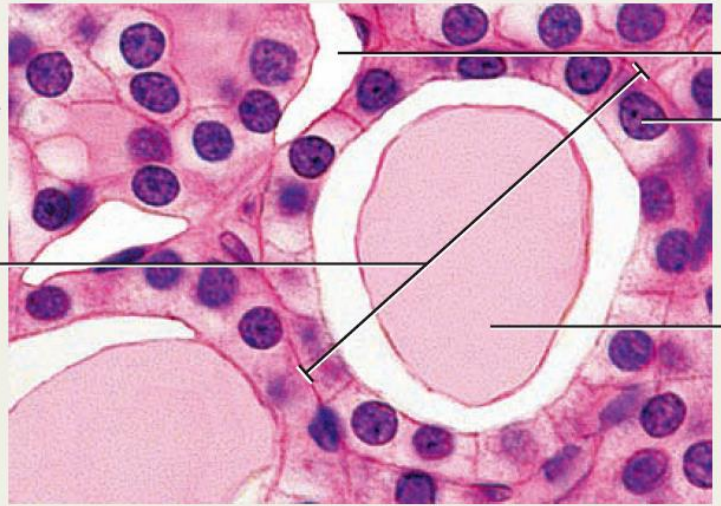

Sectional view of endocrine gland (thyroid gland)

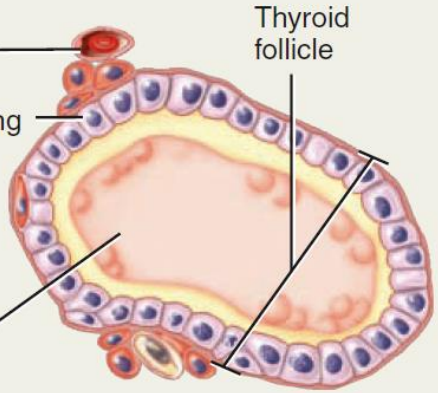

Endocrine gland (thyroid gland)

Exocrine gland

- **Description** Secretory products released into ducts that empty onto surface of a covering and lining epithelium, such as skin surface or lumen of hollow organ.
- **Location** Sweat, oil, and earwax glands of skin; digestive glands such as salivary glands (secrete into mouth cavity) and pancreas (secretes into small intestine).
- **Function** Produce substances such as sweat to help lower body temperature, oil, earwax, saliva, or digestive enzymes.

Sweat Gland

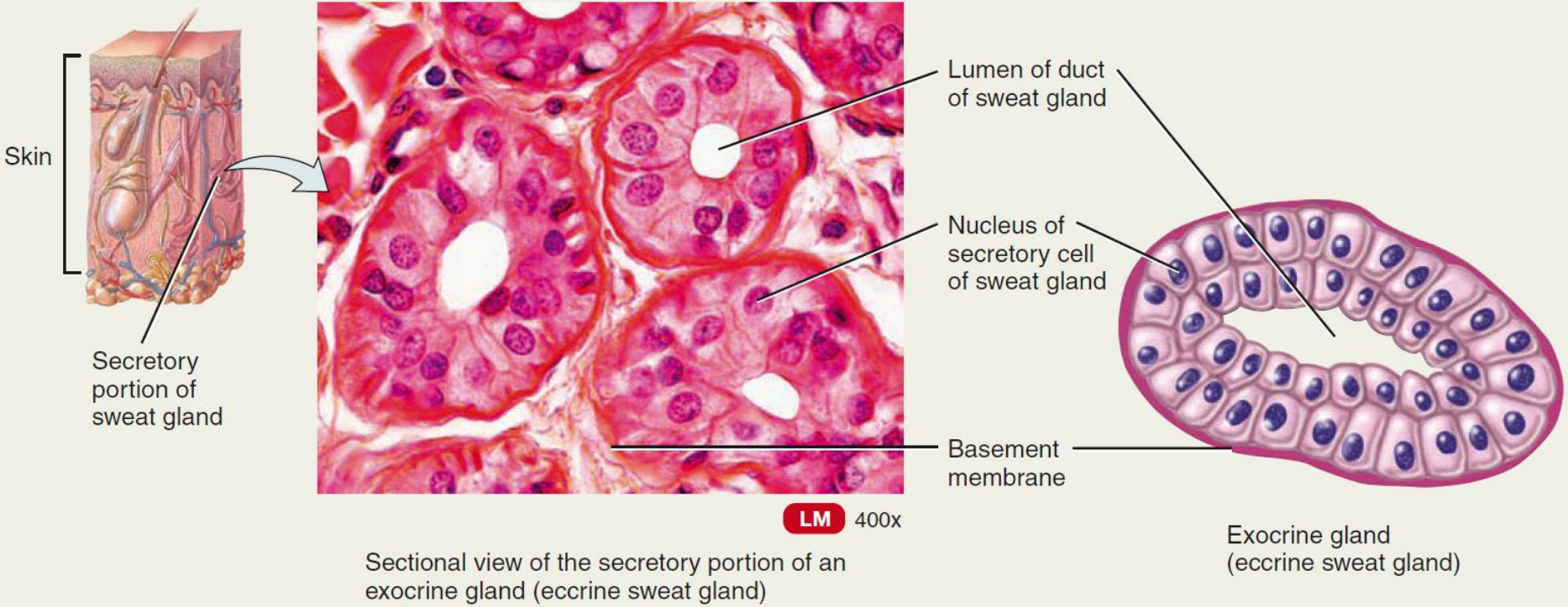
Skin
Secretory portion of sweat gland
Lumen of duct of sweat gland
Nucleus of secretory cell of sweat gland
Basement membrane
LM 400x
Sectional view of the secretory portion of an exocrine gland (eccrine sweat gland)
Exocrine gland (eccrine sweat gland)

Structural Classification of Exocrine Glands

1. **Simple glands**
   a) Simple tubular
   b) Simple branched tubular
   c) Simple coiled tubular
   d) Simple acinar
   e) Simple branched acinar
2. **Compound glands**
   a) Compound tubular.
   b) Compound acinar.
   c) Compound tubuloacinar.

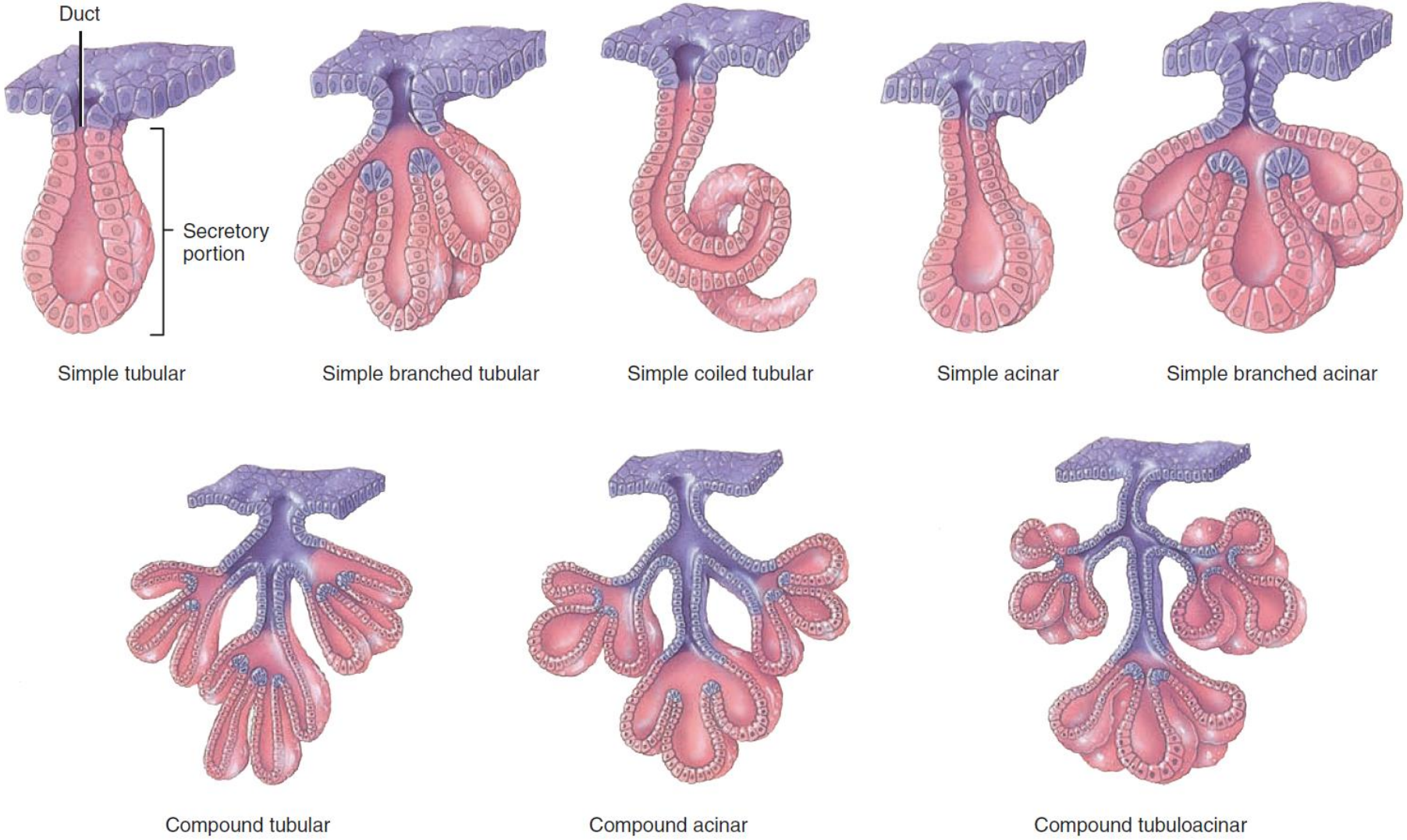
Duct
Secretory portion
Simple tubular
Simple branched tubular
Simple coiled tubular
Simple acinar
Simple branched acinar
Compound tubular
Compound acinar
Compound tubuloacinar

2. CONNECTIVE TISSUES

- **Connective tissues** are one of the most abundant and widely distributed tissues in the body
- In their various forms, connective tissues have a variety of functions.
- They bind together, support,
- and strengthen other body tissues; protect and insulate internal organs

Classification Of Connective Tissue

1. **Embryonic connective tissues**
   a) Mesenchyme
   b) Mucous connective tissue
2. **Mature connective tissues**
   a) Loose connective tissues
      - Areolar connective tissue
      - Adipose tissue
      - Reticular connective tissue
   b) Dense connective tissues
      - Dense regular connective tissue
      - Dense irregular connective tissue
      - Elastic connective tissue
   c) Cartilage
      - Hyaline cartilage
      - Fibrocartilage
      - Elastic cartilage
   d) Bone tissue
   e) Liquid connective tissue
      - Blood tissue
      - Lymph

Embryonic Connective Tissues

A. MESENCHYME

- **Description** Irregularly shaped mesenchymal cells embedded in semifluid ground substance that contains delicate reticular fibers.
- **Location** Almost exclusively under skin and along developing bones of embryo; some in adult connective tissue, especially along blood vessels.
- **Function** Forms almost all other types of connective tissue.

Function Forms almost all other types of connective tissue.

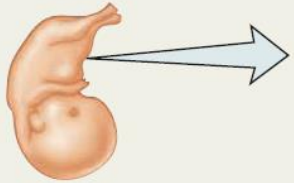

Embryo

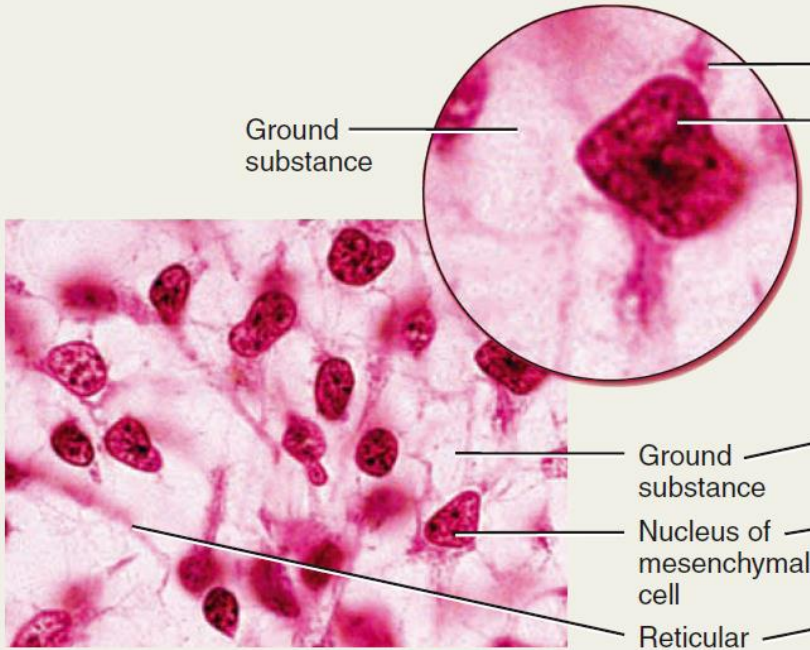

Sectional view of mesenchyme of a developing embryo

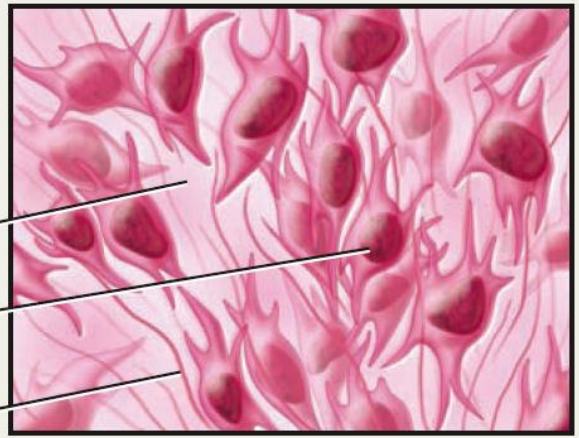

Mesenchyme

B. MUCOUS CONNECTIVE TISSUE

- **Description** Widely scattered fibroblasts embedded in viscous, jellylike ground substance that contains fine collagen fibers.
- **Location** Umbilical cord of fetus.
- **Function** Support.

MUCOUS CONNECTIVE TISSUE

Function Support.

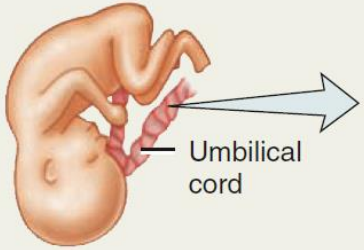

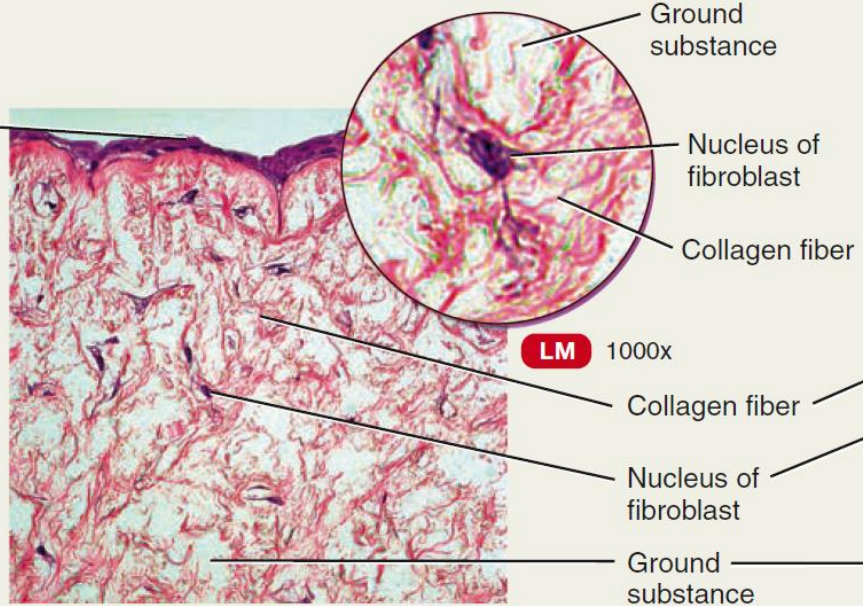

Sectional view of mucous connective tissue of the umbilical cord

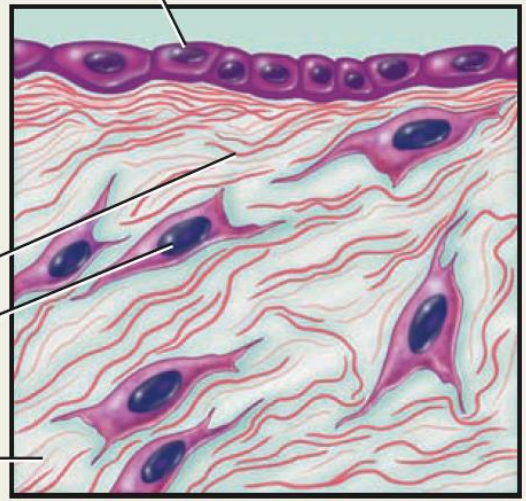

Mucous connective tissue

2. Mature connective tissues

- **Areolar connective tissue**

Description One of the most widely distributed connective tissues; consists of fibers (collagen, elastic, reticular) arranged randomly and several kinds of cells (fibroblasts, macrophages, plasma cells, adipocytes, mast cells, and a few white blood cells) embedded in semifluid ground substance (hyaluronic acid, chondroitin sulfate, dermatan sulfate, and keratan sulfate).

Location In and around nearly every body structure (thus, called "packing material" of the body): in subcutaneous layer deep to skin; papillary (superficial) region of dermis of skin; lamina propria of mucous membranes; around blood vessels, nerves, and body organs.

Function Strength, elasticity, support

Areolar connective tissue

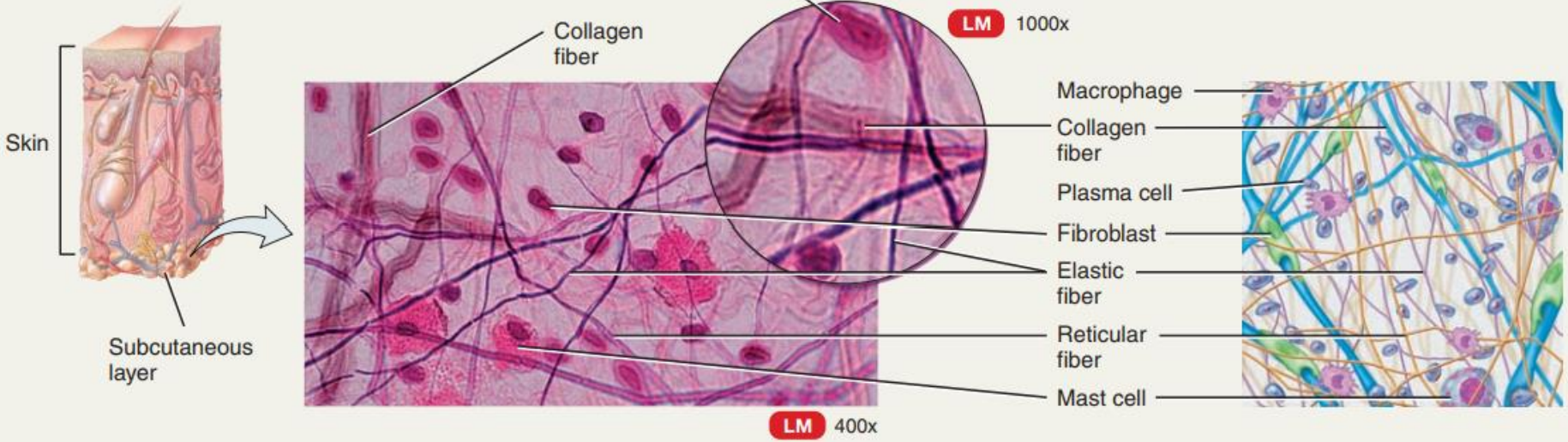

Sectional view of subcutaneous areolar connective tissue

Areolar connective tissue

ADIPOSE TISSUE

- Description Has cells derived from fibroblasts (called adipocytes) that are specialized for storage of triglycerides (fats) as a large, centrally located droplet. Cell fills up with a single, large triglyceride droplet, and cytoplasm and nucleus are pushed to periphery of cell. With weight gain, amount of adipose tissue increases and new blood vessels form.
- Location Wherever areolar connective tissue is located subcutaneous layer deep to skin, around heart and kidneys, yellow bone marrow, padding around joints and behind eyeball in eye socket.
- Function Reduces heat loss through skin; serves as an energy reserve; supports and protects organs.

ADIPOSE TISSUE

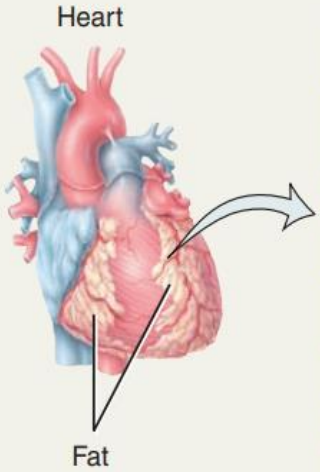

Sectional view of adipose tissue showing adipocytes of white fat and details of an adipocyte

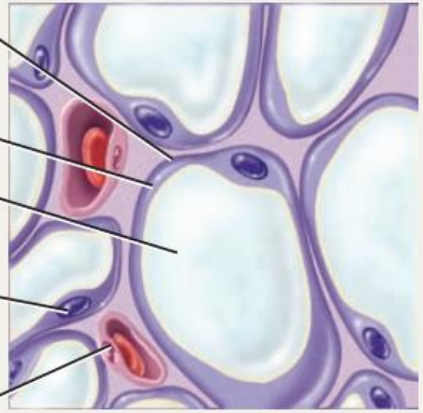

Adipose tissue

RETICULAR CONNECTIVE TISSUE

Description	**Reticular connective tissue** is a fine interlacing network of reticular fibers (thin form of collagen fiber) and reticular cells.
Location	Stroma (supporting framework) of liver, spleen, lymph nodes; red bone marrow; reticular lamina of basement membrane; around blood vessels and muscles.
Function	Forms stroma of organs; binds smooth muscle tissue cells; filters and removes worn-out blood cells in spleen and microbes in lymph nodes.

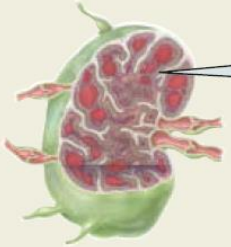

Lymph node

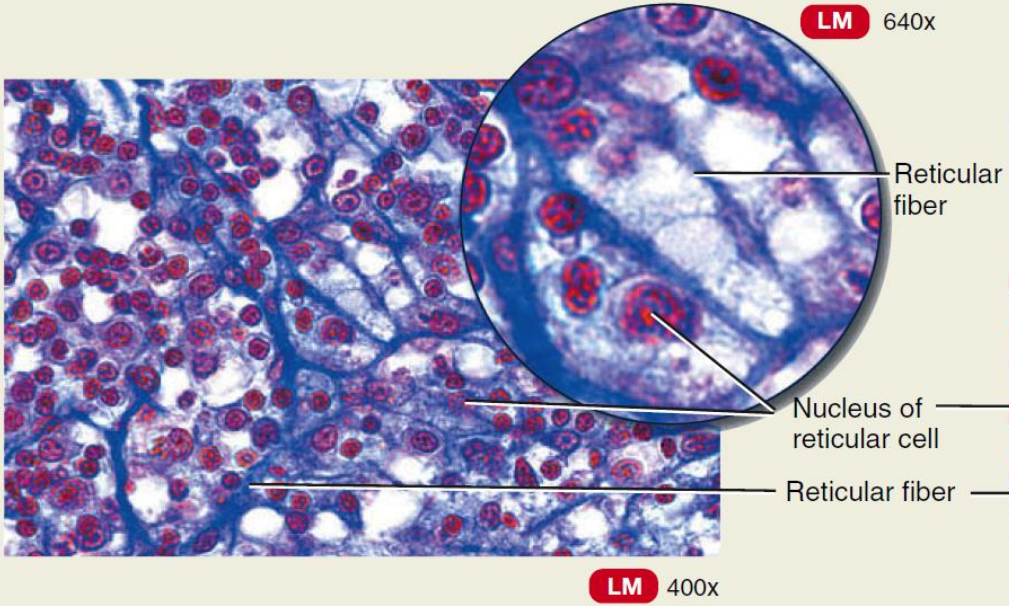

Sectional view of reticular connective tissue of a lymph node

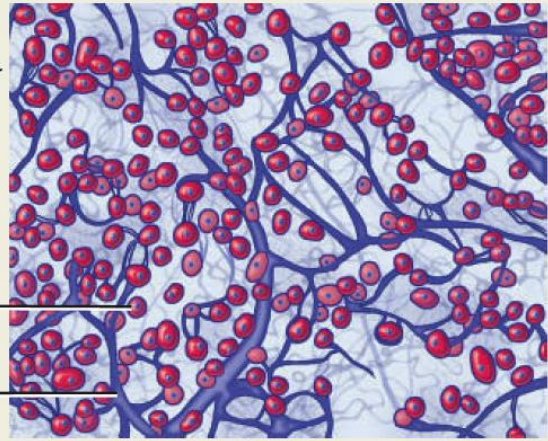

Reticular connective tissue

A. DENSE REGULAR CONNECTIVE TISSUE

Description	**Dense regular connective tissue** forms shiny white extracellular matrix; mainly collagen fibers *regularly* arranged in bundles with fibroblasts in rows between them. Collagen fibers (protein structures secreted by fibroblasts) are not living, so damaged tendons and ligaments heal slowly.
Location	Forms tendons (attach muscle to bone), most ligaments (attach bone to bone), and aponeuroses (sheetlike tendons that attach muscle to muscle or muscle to bone).
Function	Provides strong attachment between various structures. Tissue structure withstands pulling (tension) along long axis of fibers.

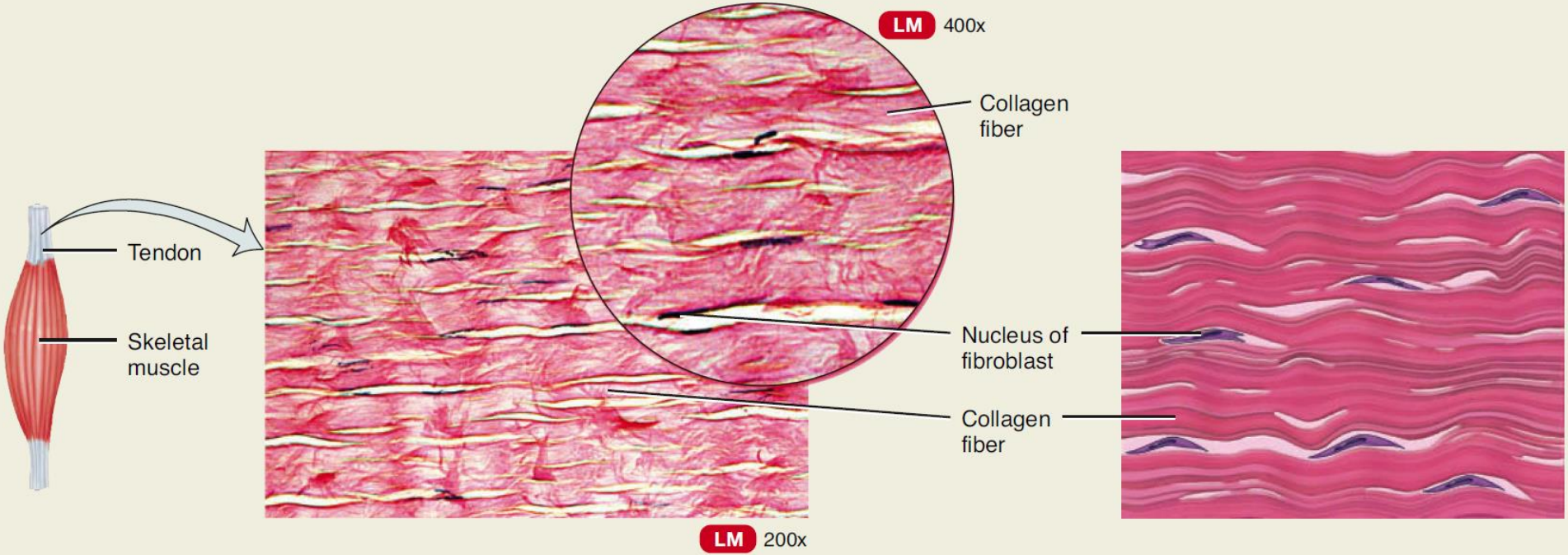

Sectional view of dense regular connective tissue of a tendon

Dense regular connective tissue

B. DENSE IRREGULAR CONNECTIVE TISSUE

Description **Dense irregular connective tissue** is made up of collagen fibers; usually *irregularly* arranged with a few fibroblasts.

Location Often occurs in sheets, such as fasciae (tissue beneath skin and around muscles and other organs), reticular (deeper) region of dermis of skin, fibrous pericardium of heart, periosteum of bone, perichondrium of cartilage, joint capsules, membrane capsules around various organs (kidneys, liver, testes, lymph nodes); also in heart valves.

Function Provides tensile (pulling) strength in many directions.

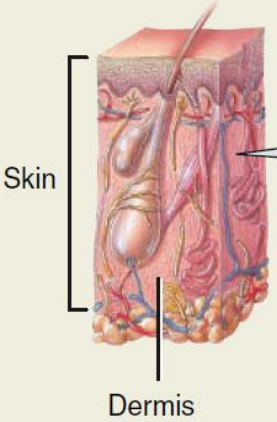

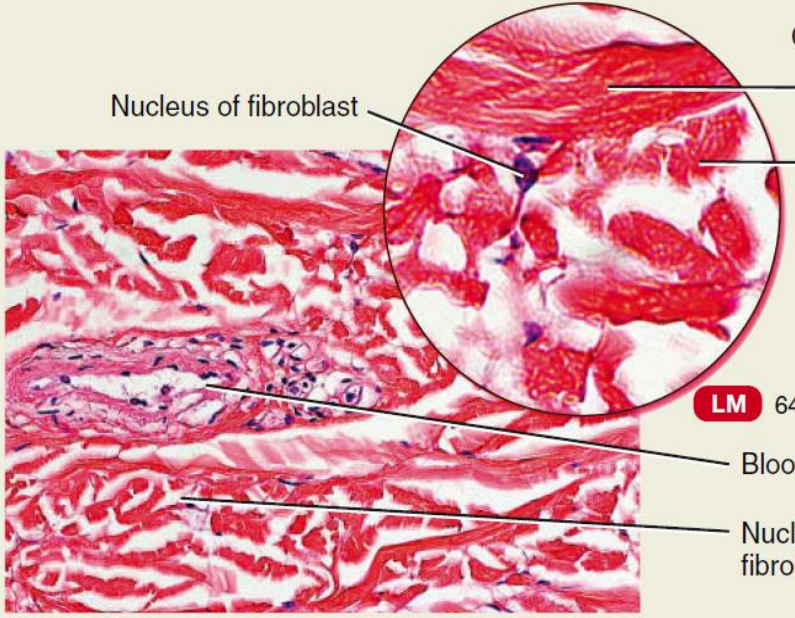

Sectional view of dense irregular connective tissue of reticular region of dermis

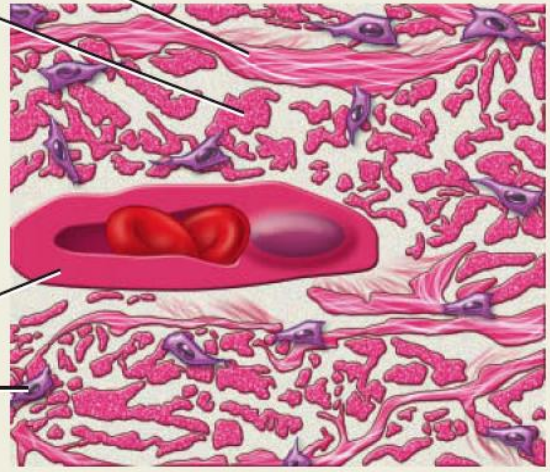

Dense irregular connective tissue

Mature Connective Tissue: Dense Connective Tissue

C. ELASTIC CONNECTIVE TISSUE

Description **Elastic connective tissue** contains predominantly elastic fibers with fibroblasts between them; unstained tissue is yellowish.

Location Lung tissue, walls of elastic arteries, trachea, bronchial tubes, true vocal cords, suspensory ligaments of penis, some ligaments between vertebrae.

Function Allows stretching of various organs; is strong and can recoil to original shape after being stretched. Elasticity is important to normal functioning of lung tissue (recoils in exhaling) and elastic arteries (recoil between heartbeats to help maintain blood flow).

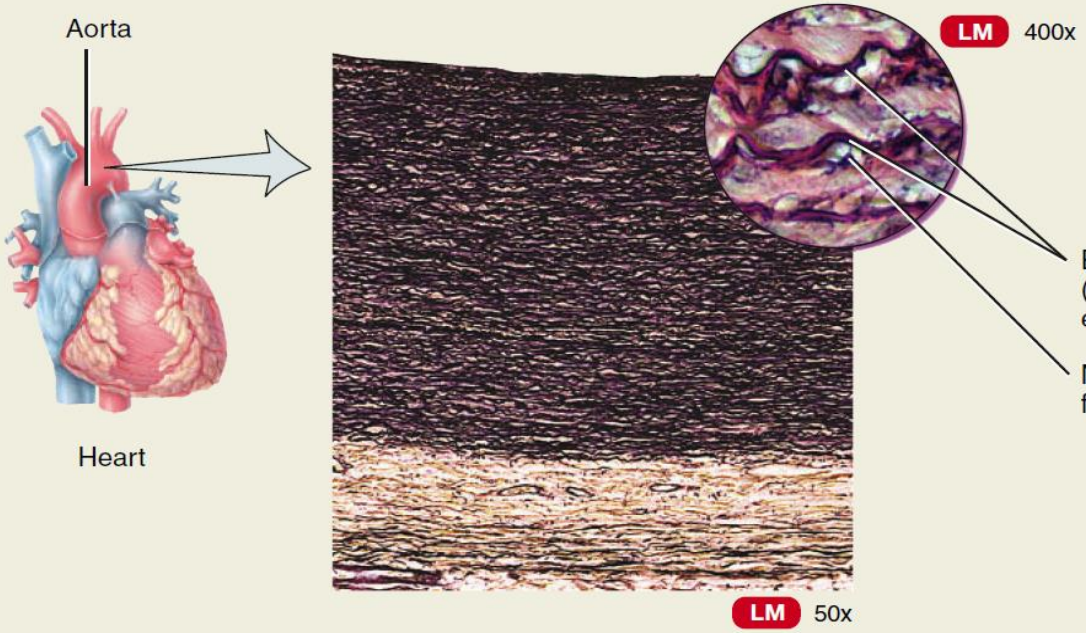

Sectional view of elastic connective tissue of aorta

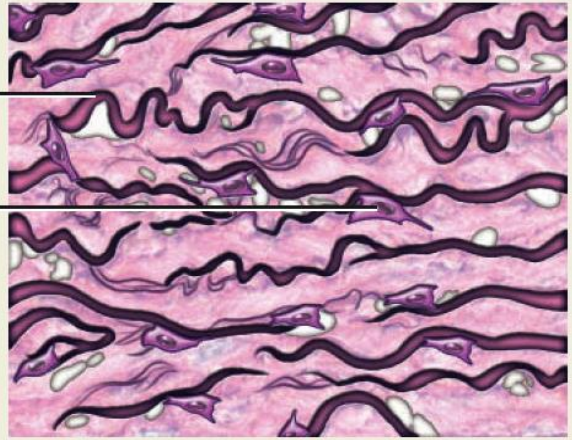

Elastic connective tissue

A. HYALINE CARTILAGE

Description **Hyaline cartilage** (*hyalinos* = glassy) contains a resilient gel as ground substance and appears in the body as a bluish-white, shiny substance (can stain pink or purple when prepared for microscopic examination; fine collagen fibers are not visible with ordinary staining techniques); prominent chondrocytes are found in lacunae surrounded by perichondrium (exceptions: articular cartilage in joints and cartilage of epiphyseal plates, where bones lengthen during growth).

Location Most abundant cartilage in body; at ends of long bones, anterior ends of ribs, nose, parts of larynx, trachea, bronchi, bronchial tubes, embryonic and fetal skeleton.

Function Provides smooth surfaces for movement at joints, flexibility, and support; weakest type of cartilage and can be fractured.

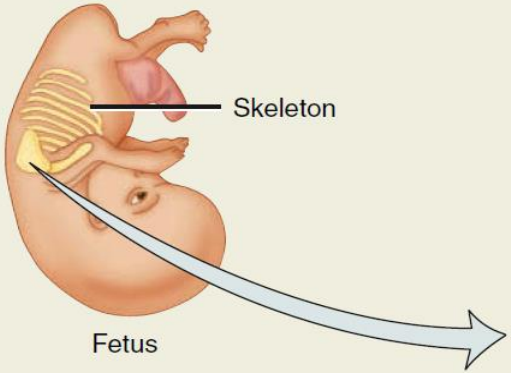

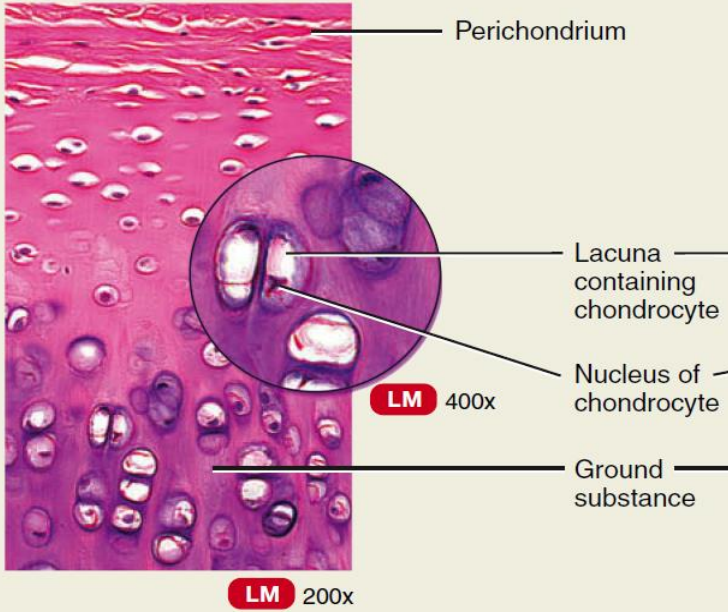

Sectional view of hyaline cartilage of a developing fetal bone

Hyaline cartilage

B. FIBROCARTILAGE

Description	**Fibrocartilage** has chondrocytes among clearly visible thick bundles of collagen fibers within extracellular matrix; lacks perichondrium.
Location	Pubic symphysis (where hip bones join anteriorly), intervertebral discs, menisci (cartilage pads) of knee, portions of tendons that insert into cartilage.
Function	Support and joining structures together. Strength and rigidity make it the strongest type of cartilage.

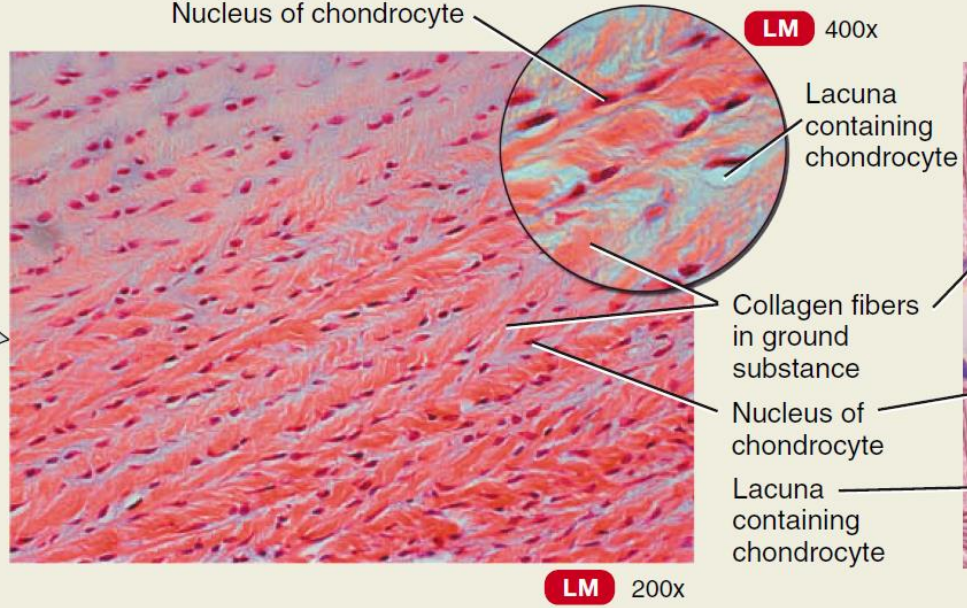

Sectional view of fibrocartilage of intervertebral disc

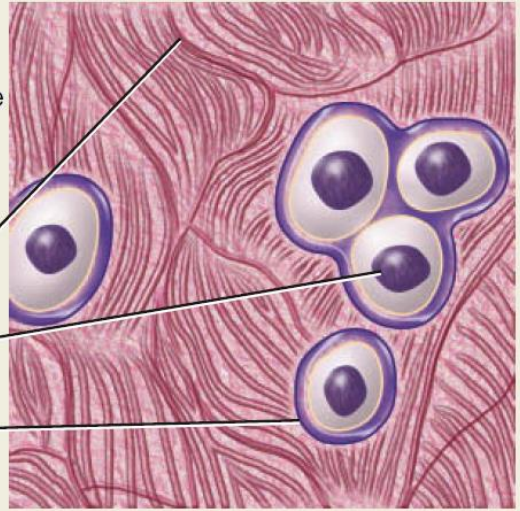

Fibrocartilage

Mature Connective Tissue: Cartilage

C. ELASTIC CARTILAGE

Description	**Elastic cartilage** has chondrocytes in threadlike network of elastic fibers within extracellular matrix; perichondrium present.
Location	Lid on top of larynx (epiglottis), part of external ear (auricle), auditory (eustachian) tubes.
Function	Provides strength and elasticity; maintains shape of certain structures.

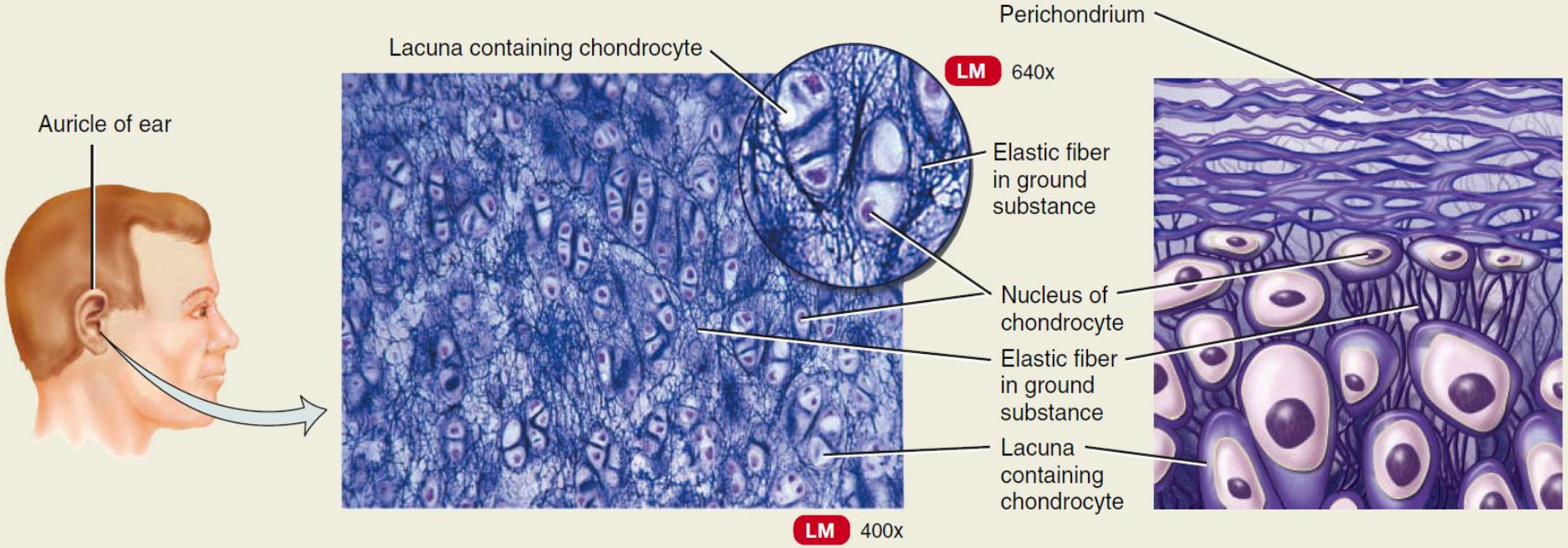

Mature Connective Tissue: Bone Tissue

Description Compact bone tissue consists of osteons (haversian systems) that contain lamellae, lacunae, osteocytes, canaliculi, and central (haversian) canals. By contrast, spongy bone tissue (see Figure 6.3) consists of thin columns called trabeculae; spaces between trabeculae are filled with red bone marrow.

Location Both compact and spongy bone tissue make up the various parts of bones of the body.

Function Support, protection, storage; houses blood-forming tissue; serves as levers that act with muscle tissue to enable movement.

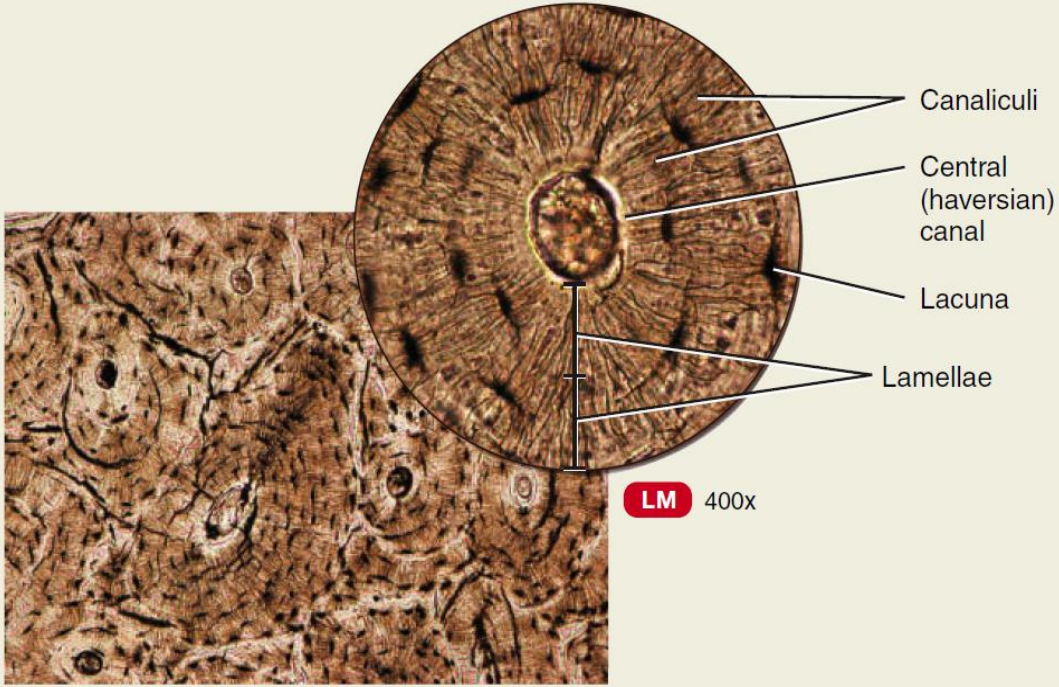

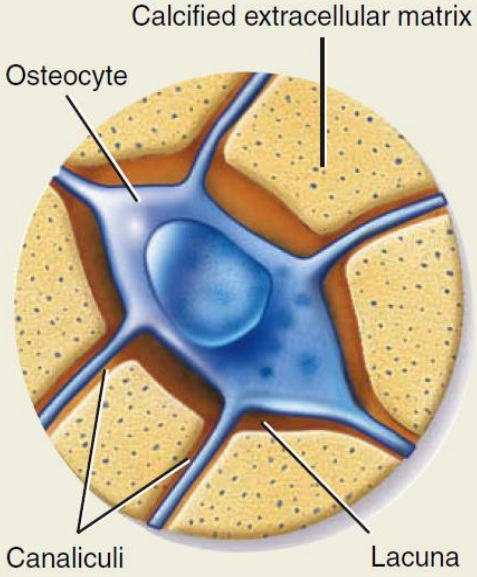

Mature Connective Tissue: Blood

Description Blood plasma and formed elements: red blood cells (erythrocytes), white blood cells (leukocytes), platelets (thrombocytes).

Location Within blood vessels (arteries, arterioles, capillaries, venules, veins), within chambers of heart.

Function Red blood cells: transport oxygen and some carbon dioxide; white blood cells: carry on phagocytosis and mediate allergic reactions and immune system responses; platelets: essential for blood clotting.

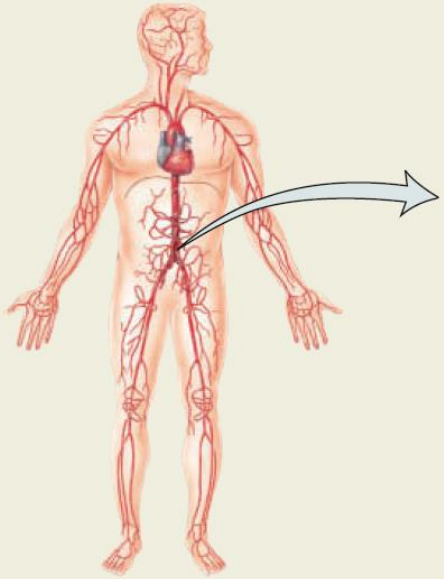

Blood in blood vessels

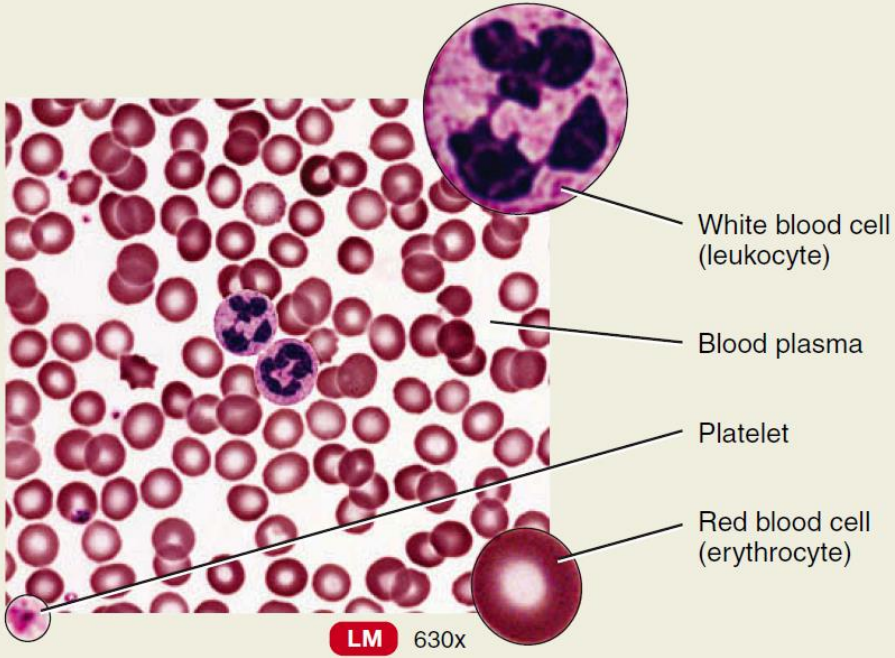

Blood smear (all enlargements are 1500x)

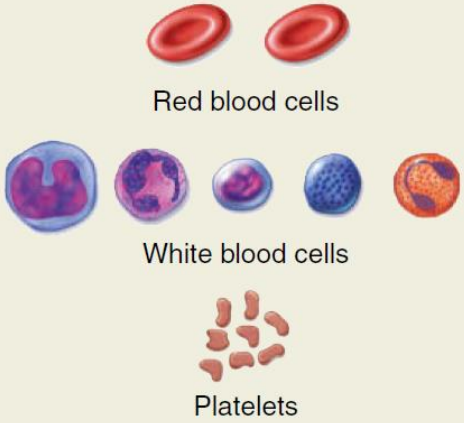

Muscular Tissue

A. SKELETAL MUSCLE TISSUE

Description **Skeletal muscle tissue** consists of long, cylindrical, striated fibers (*striations* are alternating light and dark bands within fibers that are visible under a light microscope). Skeletal muscle fibers vary greatly in length, from a few centimeters in short muscles to 30–40 cm (about 12–16 in.) in the longest muscles. A muscle fiber is a roughly cylindrical, multinucleated cell with nuclei at the periphery. Skeletal muscle is considered *voluntary* because it can be made to contract or relax by conscious control.

Location Usually attached to bones by tendons.

Function Motion, posture, heat production, protection.

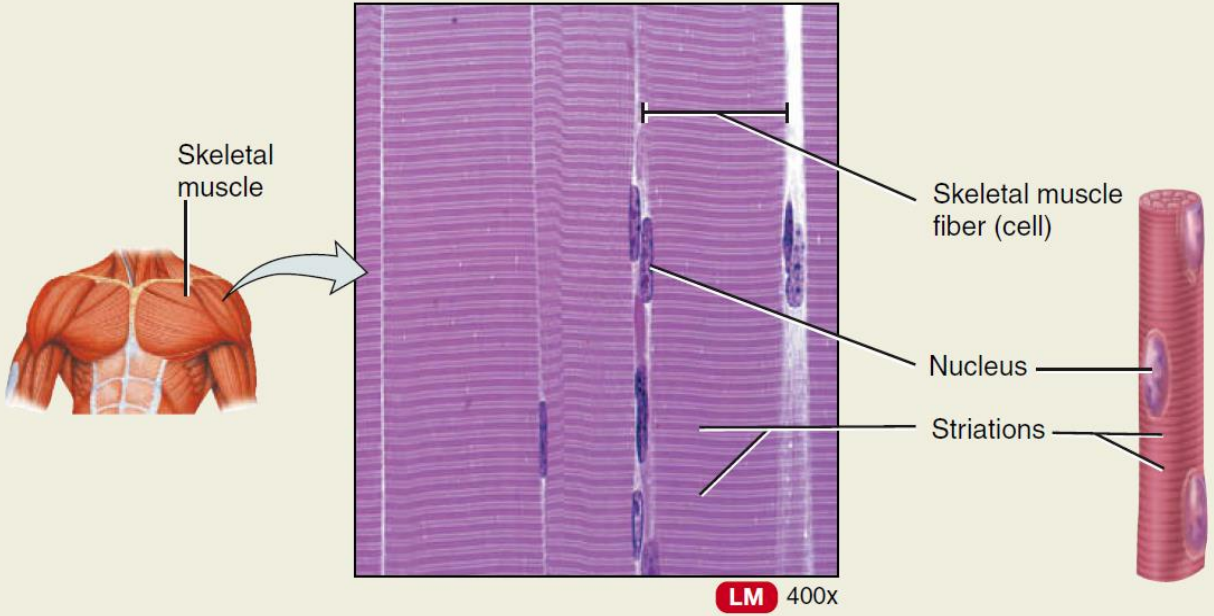

Longitudinal section of skeletal muscle tissue

Skeletal muscle fiber

B. CARDIAC MUSCLE TISSUE

Description **Cardiac muscle tissue** consists of branched, striated fibers with usually only one centrally located nucleus (occasionally two). Attach end to end by transverse thickenings of plasma membrane called *intercalated discs* (in-TER-ka-lāt-ed; *intercalate* = to insert between), which contain desmosomes and gap junctions. Desmosomes strengthen tissue and hold fibers together during vigorous contractions. Gap junctions provide route for quick conduction of electrical signals (muscle action potentials) throughout heart. *Involuntary* (not conscious) control.

Location Heart wall.

Function Pumps blood to all parts of body.

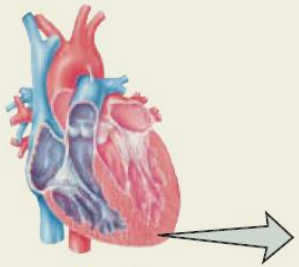

Heart

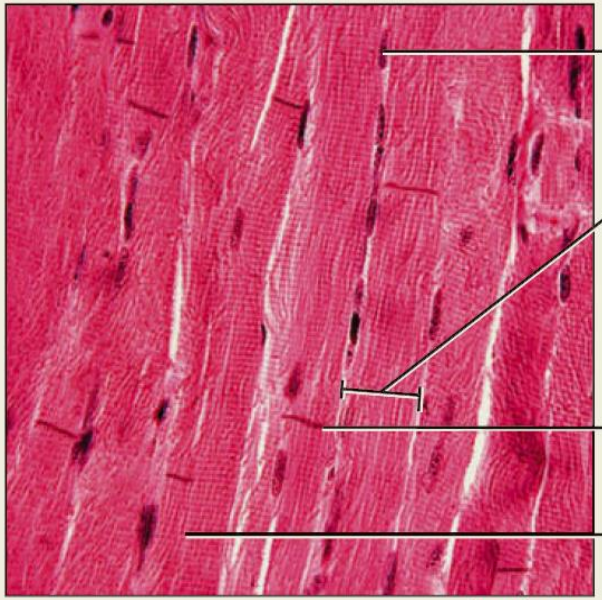

LM 500x

Longitudinal section of cardiac muscle tissue

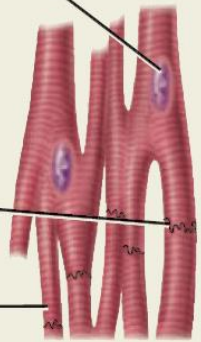

Cardiac muscle fibers

C. SMOOTH MUSCLE TISSUE

Description **Smooth muscle tissue** consists of fibers usually *involuntary,* nonstriated (lack striations, hence the term *smooth*). Smooth muscle fiber is a small spindle-shaped cell thickest in middle, tapering at each end, and containing a single, centrally located nucleus. Gap junctions connect many individual fibers in some smooth muscle tissue (for example, in wall of intestines). Can produce powerful contractions as many muscle fibers contract in unison. Where gap junctions are absent, such as iris of eye, smooth muscle fibers contract individually, like skeletal muscle fibers.

Location Iris of eyes; walls of hollow internal structures such as blood vessels, airways to lungs, stomach, intestines, gallbladder, urinary bladder, and uterus.

Function Motion (constriction of blood vessels and airways, propulsion of foods through gastrointestinal tract, contraction of urinary bladder and gallbladder).

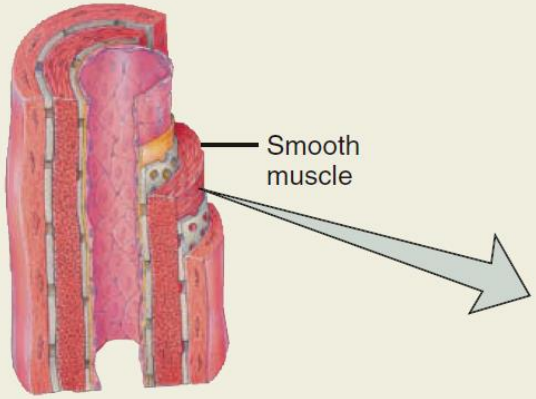

Artery

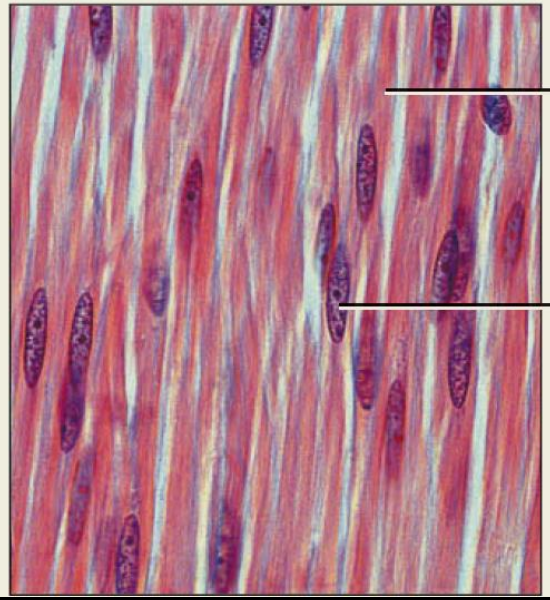

Nervous Tissue

- **Description** **Nervous tissue** consists of (1) Neurons (nerve cells), which consist of cell body and processes extending from cell body (one to multiple dendrites and a single axon); and (2) neuroglia, which do not generate or conduct nerve impulses but have other important supporting functions.
- **Location** Nervous system.
- **Function** Exhibits sensitivity to various types of stimuli; converts stimuli into nerve impulses (action potentials); conducts nerve impulses to other neurons, muscle fi bers, or glands.

Nervous tissue

- **Nervous tissue** consists of only two principal types of cells: neurons and neuroglia.
- **Neurons** or nerve cells, are sensitive to various stimuli. They convert stimuli into electrical signals called **nerve action potentials (nerve impulses)**
- **Dendrites** are tapering, highly branched, and usually short cell processes (extensions).
- The **axon** of a neuron is a single, thin, cylindrical process that may be very long. It is the output portion of a neuron, conducting nerve impulses toward another neuron or to some other tissue.

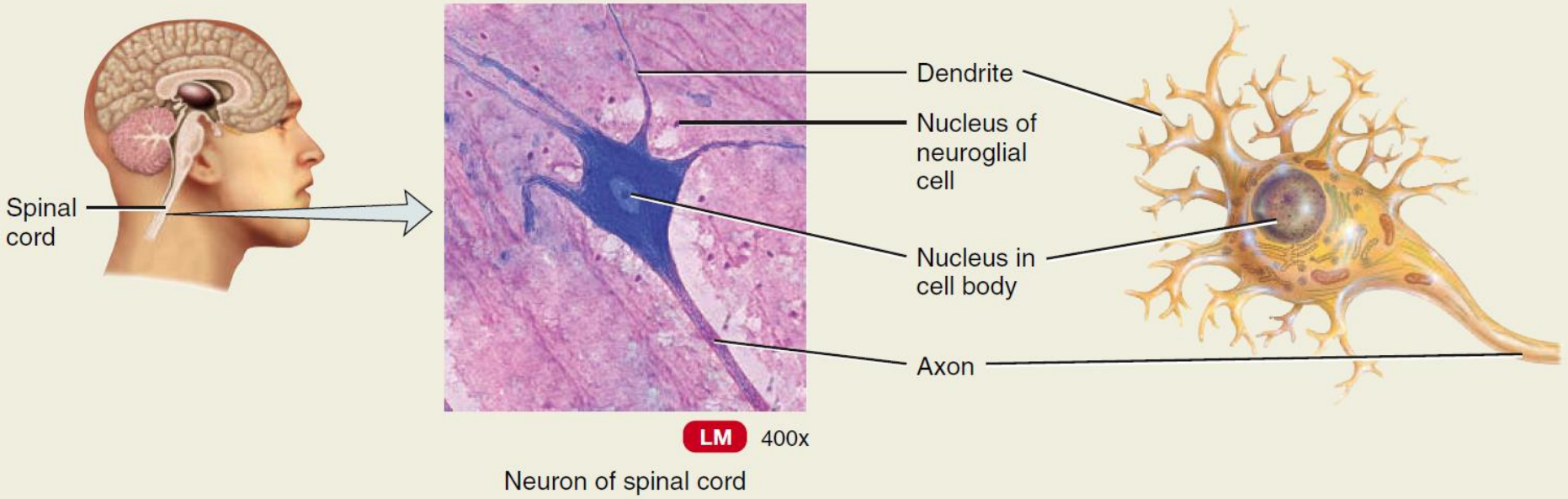

Neuron of spinal cord

Tissue Repair